

Operative Vaginal Birth: Neonatal Implications for Vacuum and Forceps-Assisted Vaginal Delivery

Tyler Lueck, MD*[†] Brett C. Young, MD*[†]

*Beth Israel Deaconess Medical Center, Boston, MA

[†]Department of Obstetrics and Gynecology, Harvard Medical School, Boston, MA

EDUCATION GAPS

Pediatricians and NICU staff are present at most operative vaginal deliveries per hospital protocol but may not be familiar with the indications for and neonatal implications of an operative-assisted vaginal delivery.

OBJECTIVES *After completing this article, readers should be able to:*

1. Define prerequisites, indications, and contraindications to operative vaginal delivery.
2. Highlight differences between vacuum- and forceps-assisted vaginal deliveries.
3. Describe neonatal risks and complications of both vacuum- and forceps-assisted vaginal deliveries.

INTRODUCTION

Operative vaginal deliveries, or vaginal deliveries performed with assistance from either a vacuum device or obstetric forceps, are a safe and effective alternative to a spontaneous vaginal delivery when maternal or fetal indications necessitate an expedited delivery. In many clinical situations, an operative vaginal delivery may reduce maternal and fetal morbidity compared to a cesarean delivery. In the United States, operative vaginal deliveries make up approximately 3% to 5% of all vaginal deliveries. (1) Indications include a wide variety of both maternal and fetal conditions and complications, including maternal cardiac or vascular conditions, maternal exhaustion, or a deteriorating fetal heart tracing. (2)(3) In the appropriately selected patient, a vacuum-assisted vaginal delivery (VAVD) or forceps-assisted vaginal delivery (FAVD) has clearly defined benefits even in the setting of potential maternal and neonatal risks. Obstetrical clinicians make a decision to proceed with operative vaginal delivery after carefully assessing the appropriate candidate, ensuring absence of any contraindications,

Drs Lueck and Young disclosed no financial relationships relevant to this article. This commentary does not contain a discussion of an unapproved/investigative use of a commercial product/device.

ABBREVIATIONS

EFW	estimated fetal weight
EGA	estimated gestational age
FAVD	forceps-assisted vaginal delivery
SVD	spontaneous vaginal delivery
VAVD	vacuum-assisted vaginal delivery

and obtaining informed consent to review the risks of the procedure. In the setting of an appropriately selected candidate, studies demonstrate high likelihood of success of operative vaginal deliveries. (4)(5)

GOALS AND SUCCESS OF OPERATIVE VAGINAL BIRTH

The goal of an operative vaginal birth, whether a VAVD or FAVD, is to achieve safe vaginal delivery for neonatal and maternal indications and prevent a cesarean delivery in the second stage of labor. There is a high likelihood of successful vaginal delivery with vacuum or forceps assistance. In a systematic review of randomized trials of nearly 3100 operative assisted vaginal births, the success of FAVD was 92% and the success of VAVD was 86% with many patients subsequently having a successful spontaneous vaginal delivery after an initial attempt at operative vaginal delivery. (4) The success rate of an attempted operative vaginal birth is dependent on many factors including a clinician's individual assessment. In a non-randomized study, of the patients that were deemed appropriate candidates for an attempted VAVD, a successful vaginal delivery was achieved for more than 95% of these patients with application of the vacuum device. (5) Operative-assisted vaginal deliveries are an effective way to prevent cesarean deliveries in the second stage of labor.

INDICATIONS

Indications for an operative vaginal delivery are the same for both VAVD and FAVD and are listed in Table 1. There are both maternal and fetal indications for operative vaginal delivery. (2)(3)

Maternal indications include a variety of different medical conditions for which prolonged valsalva in the second stage may compromise maternal status. These medical conditions include certain maternal cardiac disease (heart failure, valvular disease), vascular disease, neurologic and ophthalmologic conditions, and even some neuro-muscular diseases. Maternal exhaustion is also an indication for operative vaginal delivery.

A prolonged second stage of labor can be an indication for an operative vaginal delivery. There is no required

elapsed amount of time before an operative vaginal delivery can be offered; the decision is individualized based on the assessed likelihood of success. Considerations include parity, descent and position of fetal head, presence of epidural catheter, and effectiveness of pushing in the setting of maternal exhaustion amongst other factors.

Fetal indications for an operative vaginal delivery are determined by the fetal heart tracing. Obstetricians evaluate the fetal status by utilizing a standard interpretation system for fetal heart tracings to evaluate the likelihood of fetal acidosis. Fetal indications may include a terminal fetal bradycardia, a Category III fetal heart tracing, or concern for deteriorating fetal status.

The choice of a VAVD or FAVD depends on the clinical scenario, fetal positioning, and clinician experience and preference for each device.

BENEFITS OF OPERATIVE VAGINAL DELIVERY

Maternal Benefits

Despite their frequency, cesarean deliveries are considered a type of major surgery. Short-term and long-term morbidities following a cesarean delivery are greater than an operative-assisted vaginal delivery with longer recovery time, risk of bleeding and maternal infection, risk of blood transfusion, postoperative pain, and risk of thromboembolic events. Additionally, long-term morbidity includes the increased likelihood of repeat cesareans with an incremental increased potential of abnormal placentation. Operative vaginal deliveries can typically be accomplished more quickly than a cesarean, which may be beneficial in the setting of deteriorating fetal heart rate tracing. (6) In particular, cesarean deliveries performed during the second stage of labor are more surgically complex and have an increased incidence of surgical bleeding and postpartum hemorrhage compared to cesarean deliveries performed in early labor. Operative vaginal deliveries most often take place in the same labor room that a patient has been using and ultimately result in a vaginal delivery, which may contribute to a more standard birthing experience for the patient. For these reasons, after proper counseling and discussion of the risks, operative vaginal delivery is an appropriate option for patients.

Table 1. Indications for Operative Vaginal Delivery

Maternal	Maternal medical conditions in which pushing or prolonged second stage are contraindicated or may promote compromise of the maternal condition, including vascular, cardiac, or pulmonary indications. Maternal exhaustion or inability to push
Fetal	Deterioration or expected deterioration in fetal status
Both	Prolonged second stage

Table 2. Prerequisites for Operative Vaginal Delivery

Patient counseled and consented; conversation must include indications, benefits, risks, and alternatives to operative vaginal delivery
Patient must be willing to proceed with cesarean delivery if operative vaginal delivery is not successful
Assessment of pelvic adequacy
Estimation of fetal weight
Full cervical dilation
Rupture of membranes
Cephalic presentation
Known fetal station and position
Engagement of the fetal head
Drainage of maternal bladder
Adequate anesthesia
VAVD only: EGA >34 weeks

Neonatal Benefits

If immediate delivery is indicated for fetal bradycardia or deteriorating fetal testing, an operative vaginal delivery typically is the fastest way to deliver the neonate given that it can most often be performed in the same labor room that the patient has been using. An operative vaginal delivery allows the neonate to be placed directly on the maternal chest promoting skin-skin contact, which may be difficult in the operative room during a cesarean delivery.

PREREQUISITES

Before an operative vaginal delivery can be performed, thorough maternal and fetal assessment by the obstetrician is required to determine if the patient meets prerequisites to be considered an appropriate candidate for either a VAVD or FAVD, as listed in Table 2. (2)(3) First, the patient must be thoroughly counseled on the benefits and risks of an operative vaginal delivery, including the alternatives of ongoing spontaneous expulsive efforts or cesarean delivery.

In order to optimize success of an operative vaginal delivery, an obstetrician needs to assess fetal size and positioning in conjunction with a physical assessment of the adequacy of the maternal pelvis. A pelvic exam is performed by the obstetrician, which includes assessing pelvic adequacy and confirming full cervical dilation and rupture of membranes. During the pelvic exam, the obstetrician must determine the fetal station and position. The head must be engaged in the maternal pelvis and meet minimum levels of descent into the maternal

pelvis. The fetal position is important to determine correct positioning of the vacuum device or forceps.

CONTRAINDICATIONS

Few contraindications exist for operative vaginal delivery, which are outlined in Table 3. For any operative vaginal delivery, the previously discussed prerequisites must be met. If there is high clinical concern for certain fetal bleeding disorders and bone demineralizing diseases, operative vaginal delivery is contraindicated. If an obstetrician feels that the maternal pelvis is not sufficient for a vaginal delivery, a VAVD or FAVD should not be performed.

Specifically for VAVD, the minimum gestational age is typically greater than 34 weeks' gestation although a safe lower gestational age limit has not been established. (2) There may be select indications where expedited delivery of a neonate less than 34 weeks' gestation via VAVD may be beneficial (see Table 3).

VACUUM OVERVIEW

Types

In general, there are two predominant modern-day kinds of vacuum devices available: soft or rigid plastic cups. There is not thought to be clinical differences in outcomes between the two styles of vacuum. (2) Typically an obstetrical clinician chooses a vacuum device based on individual preference and experience with the device. Examples of two vacuum devices are pictured in Figures 1 and 2. Vacuum

Table 3. Contraindications to Operative Vaginal Delivery

Prerequisites not met (see Table 2)
Fetal bleeding disorder including alloimmune thrombocytopenia, hemophilia, von Willebrand's disease
Fetal bone mineralization disorder (osteogenesis imperfecta)
<34 weeks' gestation for VAVD

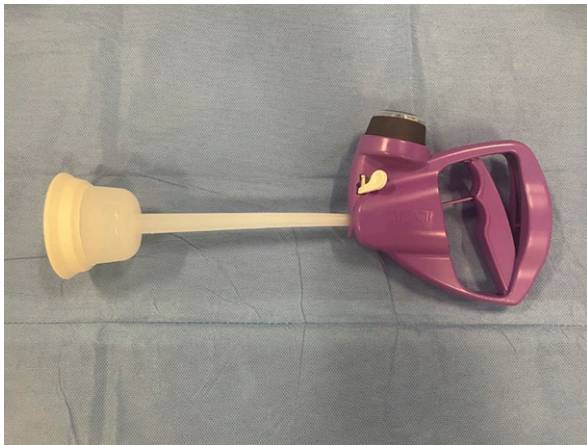

Figure 1. Example of soft cup vacuum device. Photo courtesy of Dr. Tyler Lueck.

devices have a pressure gauge built into the device to allow the obstetrician performing the VAVD to safely apply pressure to the fetal head, pictured in Figure 3.

Basics of VAVD

After a patient has been deemed an appropriate candidate for a VAVD and prerequisites have been met, the vacuum device is applied to the fetal head. Routine antibiotics and episiotomy are not recommended. (6) Proper positioning of the vacuum device involves placing the cup along the sagittal suture 2 centimeters anterior to the posterior fontanelle. An exam is performed to ensure no maternal tissue is between the cup and fetal head. The suction is then activated and maintained in the safety zone as indicated on the vacuum device, as pictured in Figure 3.

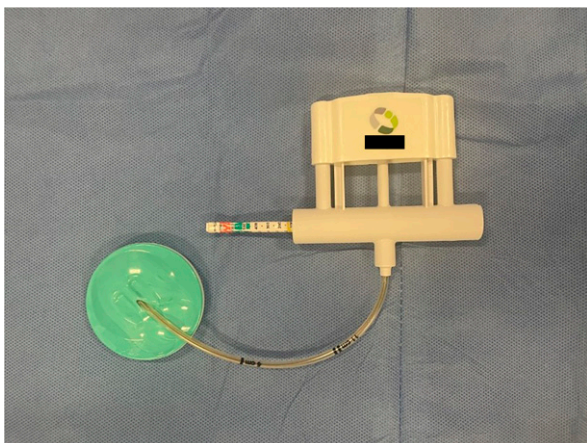


Figure 2. Example of rigid cup vacuum device. Photo courtesy of Dr. Tyler Lueck.

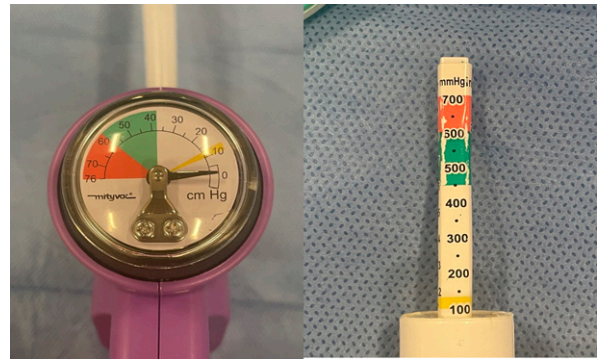


Figure 3. Safety zone indicators for different vacuum devices. Photo courtesy of Dr. Tyler Lueck.

Gentle downward traction is then applied by the obstetrician performing the VAVD during contractions to supplement maternal effort. In the setting of fetal compromise or contraindications to maternal pushing, the VAVD may be performed without contractions or maternal effort. Traction is applied via the vacuum device to guide the fetal head through the pelvis for a successful delivery. The vacuum device is then removed after delivery of the fetal head to facilitate delivery of the rest of the neonate. (2)

FORCEPS OVERVIEW

Types

Many different kinds of obstetric forceps exist. Forceps provide a more secure application to the fetal head compared to vacuum devices though there is a higher likelihood of more severe maternal perineal laceration. (2)(3)(4)(5)(6) The choice of forceps depends on the clinical scenario, which is beyond the scope of this review. Additionally, the type of forceps chosen may be dependent on the clinician's individual preference. A few examples of obstetric forceps are pictured in Figures 4 and 5.

Basics of FAVD

Similar to a VAVD, once a patient has been counseled, selected as an appropriate candidate, and prerequisites have been met, the forceps are applied to the fetal head. The forceps are placed in a direction from the occiput toward the fetal chin so that the blades rest against the fetal cheeks. The obstetrician must ensure that no maternal tissue has been caught between the forceps and fetal head. The forceps blades are then articulated. Traction is then applied to guide the fetal head through the maternal pelvis. Similar to a VAVD, traction is typically applied during




Figure 4. Simpson forceps. Photo courtesy of Dr. Tyler Lueck.

pushing and uterine contractions, though may be applied independent of maternal valsalva depending on the clinical scenario.

MATERNAL COMPLICATIONS

Maternal complications from a VAVD or FAVD include an increased risk for more complex perineal tears that involve the anal sphincter muscles and rectal mucosa compared to a spontaneous vaginal delivery. (2)(3)(4)(5)(6) Despite the increased risk of third and fourth degree perineal lacerations with VAVD or FAVD, other risk factors such as macrosomia or prolonged second stage of labor are other causal clinical factors that are associated with operative vaginal delivery. The exact contribution of these clinical factors versus the use of vacuum or forceps is difficult to discern. If the operative delivery is not successful, sequential use of both vacuum and forceps is typically not

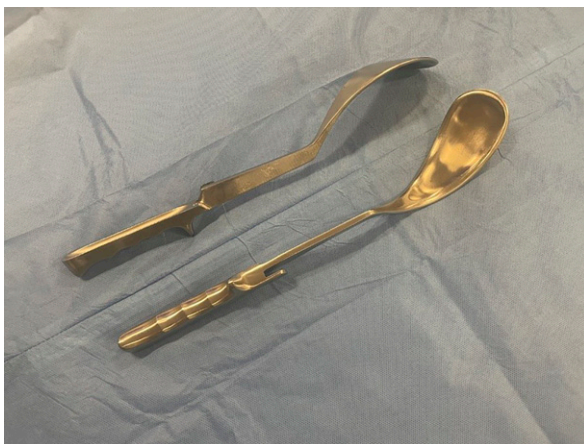

Figure 5. Tucker-McLean-Luikart forceps. Photo courtesy of Dr. Tyler Lueck.

advised given the increased likelihood of neonatal neurologic injury. (7) Therefore, if the operative vaginal delivery is not successful with one device, typically a cesarean is the next step for delivery. As described above, a cesarean delivery in the second stage of labor has increased morbidity compared to a scheduled cesarean without labor.

NEONATAL COMPLICATIONS

The risk of neonatal complications from operative vaginal delivery remains low particularly with an appropriately selected candidate. The risk of intracranial hemorrhage from large cohort studies is estimated to be 1 in every 650 to 850 operative vaginal deliveries. (7) Data indicate that the risk of neonatal intracranial hemorrhage is similar for FAVD, VAVD, and intrapartum cesareans. (7) The etiology of some neonatal neurologic sequelae is thought to be associated with the underlying indication for the operative vaginal delivery. The risk of neurologic sequelae is not expected to be lower in the setting of a subsequent cesarean delivery after a failed operative vaginal delivery attempt as an operative vaginal delivery can be completed more quickly than a cesarean delivery. (2) The rates of neonatal intracranial hemorrhage were similar for vacuum, forceps, and cesarean deliveries that were performed in labor. (7)

While the rate of neonatal injuries remains low, the type of neonatal injuries reported with operative vaginal deliveries vary with the type of instrument used. VAVDs are mostly related to the vacuum device placement on the fetal scalp and may result in cephalohematoma, scalp laceration, retinal hemorrhage, and intracranial hemorrhage. (2) Traction and suction generated by the vacuum device can cause trauma within various spaces of the fetal scalp and skull. The most superficial of these spaces is swelling within the scalp soft tissue, also known as a caput succedaneum. A cephalohematoma occurs when there is bleeding between the periosteum and skull. This type of hemorrhage is often contained to a single skull bone and therefore, does not spread rapidly. Cephalohematomas are more common with VAVD compared to FAVD, occurring in 15% vs 2% of these deliveries, respectively. (6)

Subgaleal hematomas form due to bleeding beneath the galea aponeurotica. Subgaleal hematomas can rapidly expand across the entire skull within this potential space. Fortunately, subgaleal hematomas are rare, occurring in less than 0.04% of VAVD (Figure 6) (6). There is an association between the likelihood of failed vacuum delivery and the number of spontaneous pop-offs; similarly, there was an association between composite adverse neonatal outcome and both the number of spontaneous vacuum

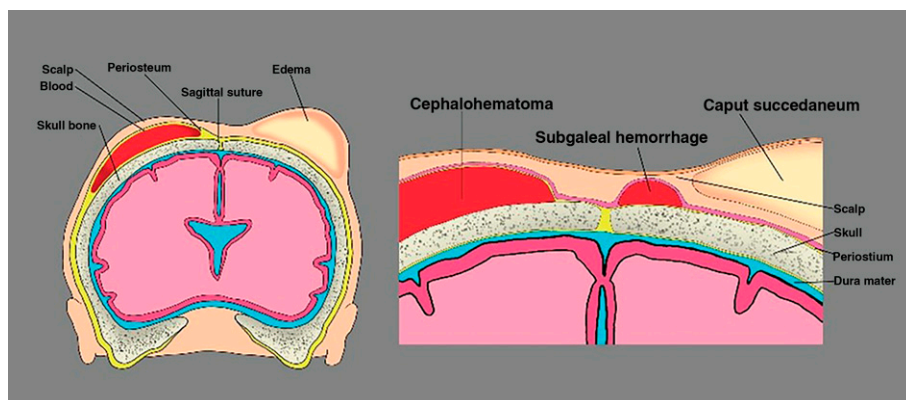


Figure 6. Possible neonatal intracranial birth injuries after operative vaginal delivery. The risk of intracranial birth injuries following operative vaginal delivery with forceps or vacuum deliveries remains low. Reprinted with permission from Statpearls: “Cephalohematoma” Illustration by Chelsea Rowe. statpearls.com/ArticleLibrary/viewarticle/19156. Accessed July 14, 2022.

detachments and a longer duration of the VAVD. (8) Of note, it is unknown how a subsequent cesarean delivery after a failed VAVD impacts these neonatal risks.

FAVD may result in neonatal facial lacerations, facial nerve palsy, corneal abrasions and external ocular injury, skull fracture, and intracranial hemorrhage. Facial lacerations and facial nerve palsies from the forceps blades may occur. The facial nerve palsies are typically temporary. Additionally, ocular trauma, such as corneal abrasions, are possible with suboptimally placed forceps. Compared to neonates delivered via an unscheduled cesarean in labor, neonates born via FAVD have higher rates of skull fracture, facial nerve palsy, retinal hemorrhage, and brachial plexus injury and yet lower rates of seizures, intraventricular hemorrhage, and subdural hemorrhage. (2) Brachial plexus injuries may occur when a shoulder is impacted within the maternal pelvis.

While neonatal intracranial injuries are rare, studies demonstrate an increased likelihood of neonatal intracranial hemorrhagic injury with sequential use of forceps and vacuum and therefore, serial use of both forceps and vacuum on the same patient is typically avoided. (7)

Given the rare but possible severity of fetal complications related to both VAVD and FAVD, prompt evaluation by pediatrics is indicated for infants born via operative vaginal deliveries. Most injuries are apparent within the first few hours after birth. (6)

Long-term Neonatal Sequelae

Available studies demonstrate similar long-term neurocognitive outcomes for children born via vacuum or forceps compared to children born via spontaneous vaginal birth. (9) Data demonstrate that there is no long-term neurocognitive difference between neonates born via VAVD vs FAVD; another study

demonstrated similar long-term outcomes for children born via spontaneous vaginal delivery and VAVD. (6)

Summary

- Operative vaginal delivery, both VAVD and FAVD, is a safe alternative to cesarean delivery when expedited delivery is indicated for maternal or fetal indications.
- If indicated, prior to performing an operative vaginal delivery, obstetricians perform a thorough maternal and fetal evaluation to ensure appropriate candidacy and adequacy of the maternal pelvis.
- Maternal complications from an operative vaginal delivery include increased complexity of perineal tears which are frequently more severe with FAVD.
- Fetal complications rarely include intracranial hemorrhage so prompt evaluation by pediatrics is routinely indicated for all operative vaginal deliveries.

American Board of Pediatrics Neonatal-Perinatal Content Specifications

- Recognize which patients may be candidates for an operative vaginal delivery.
- Identify the basic steps of performing a vacuum- and forceps-assisted vaginal delivery.
- Recognize both the maternal and fetal risks associated with operative vaginal deliveries.

References

1. Martin JA, Hamilton BE, Osterman MJK, Driscoll AK, Drake P. Births: Final Data for 2017. *Natl Vital Stat Rep*. 2018;67(8):1–50
2. American College of Obstetricians and Gynecologists. Operative vaginal birth. ACOG Practice Bulletin No. 219. *Obstet Gynecol*. 2020;135:e149–e159
3. Patient Safety and Quality Committee, Society for Maternal-Fetal Medicine; Staat B, Combs CA. SMFM Special Statement: Operative Vaginal Delivery: Checklists for Performance and Documentation. *Am J Obstet Gynecol*. 2020;222(5):PB15–PB21
4. Verma GL, Spalding JJ, Wilkinson MD, Hofmeyr GJ, Vannevel V, O'Mahony F. Instruments for assisted vaginal birth. *Cochrane Database Syst Rev*. 2021;9:CD005455
5. Ramos SZ, Waring ME, Leung K, Amir NS, Bannon AL, Moore Simas TA. Attempted and successful vacuum-assisted vaginal delivery by prepregnancy body mass index. *Obstet Gynecol*. 2017;129(2):311–320
6. Ali UA, Norwitz ER. Vacuum-assisted vaginal delivery. *Rev Obstet Gynecol*. 2009;2(1):5–17
7. Towner D, Castro MA, Eby-Wilkens E, Gilbert WM. Effect of mode of delivery in nulliparous women on neonatal intracranial injury. *N Engl J Med*. 1999;341(23):1709–1714
8. Miller ES, Lai Y, Bailit J, et al; Eunice Kennedy Shriver National Institute of Child Health Human Development Maternal-Fetal Medicine Units Network*. Duration of operative vaginal delivery and adverse obstetric outcomes. *Am J Perinatol*. 2020;37(5):503–510
9. Wesley BD, van den Berg BJ, Reece EA. The effect of forceps delivery on cognitive development. *Am J Obstet Gynecol*. 1993;169(5):1091–1095



- Operative vaginal deliveries performed with the assistance from either a vacuum (vacuum-assisted vaginal delivery, VAVD) or forceps (forceps-assisted vaginal delivery, FAVD) can achieve the goals of a safe vaginal delivery for specific maternal and neonatal indications. Which of the following statements regarding operative vaginal deliveries is INCORRECT?
 - In the United States, operative vaginal deliveries account for 3% to 5% of all vaginal deliveries.
 - Operative-assisted vaginal deliveries are an effective way to prevent cesarean deliveries in the second stage of labor.
 - In a systematic review of randomized trials, the success of FAVD was found to be greater than 90% in appropriately selected patients.
 - The sequential use of both vacuum and forceps is not recommended due to the increased likelihood of neonatal intracranial hemorrhage.
 - In a systematic review, the likelihood (?) of having a successful VAVD was found to be greater than 98% for vaginal delivery.
- A few fetal conditions represent contraindications to operative vaginal deliveries. These include the presence of a fetal bleeding disorder or fetal bone mineralization disorder. In addition, the gestational age (GA) should also be taken into consideration. What is the minimum GA typically felt to be safe for the use of VAVD?
 - 31 weeks' GA.
 - 32 weeks' GA.
 - 33 weeks' GA.
 - 34 weeks' GA.
 - 35 weeks' GA.
- Cesarean deliveries, particularly those performed during the second stage of labor, have greater risk of both short- and long-term morbidities for the mother. Which of the following maternal morbidities associated with a cesarean delivery is particularly increased when a cesarean is performed in the second stage of labor compared to early labor?
 - Maternal infection.
 - Thromboembolism.
 - Abnormal placentation in subsequent pregnancies.
 - Postpartum depression.
 - Postpartum hemorrhage.
- In appropriately selected patients, the risk of neonatal complications from operative vaginal delivery remains low, estimated to be 1 in every 650 to 850 operative vaginal deliveries. The type of neonatal injury differs between VAVD and FAVD. Which of the following statements describes a neonatal complication that would more likely have resulted from VAVD and not FAVD?
 - Neonatal facial laceration.
 - Skull fracture.
 - Corneal abrasion.
 - Subgaleal hemorrhage.
 - Facial nerve palsy.

REQUIREMENTS: Learners can take *NeoReviews* quizzes and claim credit online only at: <https://publications.aap.org/neoreviews>.

To successfully complete 2023 *NeoReviews* articles for *AMA PRA Category 1 Credit™*, learners must demonstrate a minimum performance level of 60% or higher on this assessment. If you score less than 60% on the assessment, you will be given additional opportunities to answer questions until an overall 60% or greater score is achieved.

This journal-based CME activity is available through Dec. 31, 2025, however, credit will be recorded in the year in which the learner completes the quiz.



2023 *NeoReviews* is approved for a total of 30 Maintenance of Certification (MOC) Part 2 credits by the American Board of Pediatrics (ABP) through the AAP MOC Portfolio Program. *NeoReviews* subscribers can claim up to 30 ABP MOC Part 2 points upon passing 30 quizzes (and claiming full credit for each quiz) per year. Subscribers can start claiming MOC credits as early as October 2023. To learn how to claim MOC points, go to: <https://publications.aap.org/journals/pages/moc-credit>.

5. Cephalohematomas, characterized by a subperiosteal bleeding delineated by suture lines, are more common with VAVD compared to FAVD. What is the incidence of cephalohematomas in VAVD?

- A. 15%.
- B. 30%.
- C. 5%.
- D. 10%.
- E. 40%.