

Tinea Corporis and Tinea Capitis

Rosemary Shy, MD*

Author Disclosure
Dr Shy did not disclose any financial relationships relevant to this article.

Objectives After completing this article, readers should be able to:

1. Recognize the wide variation in presentations of tinea capitis and corporis.
2. Describe that treatment of hair, nails, and beard compared with that for other body sites.
3. Discuss the causes and management of tinea capitis and corporis.
4. Explain why systemic therapy is necessary to eradicate tinea capitis.

Introduction

Tinea is a geographically widespread group of fungal infections caused by dermatophytes. Predominance of type depends on the organism, its hosts, and local factors. Infection may occur through contact with infected humans and animals, soil, or inanimate objects. Tinea should be suspected in any red, scaly, pruritic, enlarging lesion or in pruritic scalp lesions that manifest scaling, folliculitis, or an inflammatory reaction.

Gruby, Remak, and Schonlein described the causes of favic tinea in the early 1800s. In the early 1900s, Sabouraud classified the dermatophytic fungi. In the 1950s, Kligman further described the natural course and pathogenesis of these infections. In 1958, treatment with oral griseofulvin was introduced, obviating the need to use epilation with radiography or thallium. More recent antifungal medications, the azoles, allylamines, and benzylamines, offer new options of shorter and more convenient dosing regimens.

Definitions

Tinea is a superficial infection of the skin, scalp, nails, or hair caused by dermatophytic fungi that invade the stratum corneum and use keratin as a nutrient source.

Dermatophytes have three genera: *Trichophyton*, *Epidermophyton*, and *Microsporum*. The site of formation of arthroconidia, the spore-forming bodies of the dermatophyte, classifies the species causing tinea capitis. Ectothrix species form conidia around the hair shaft and beneath the cuticle of hair. Endothrix species have arthrospores present within the hair shaft. The favic species have hyphae arranged in parallel within and around the hair shaft. For example, *T tonsurans* is endothrix, *M audouinii* is ectothrix, and *T schoenleinii* is favic.

Specific organisms tend to cause infection in specific geographic areas or body sites. Often the pattern of involvement depends on the anatomic site, and the specific condition is so named (Table 1). Dermatophytes are classified according to their primary host as anthropophilic, zoophilic, or geophilic. Anthropophilic dermatophytes are adapted to human keratin and affect humans primarily. These organisms often infect areas of covered or traumatized skin. Zoophilic organisms are hosted primarily by animals and commonly affect exposed areas such as the face, neck, and arms. Geophilic dermatophytes reside in the soil.

Epidemiology

Although tinea infections are distributed worldwide, geography often determines the occurrence and prevalence. In the United States, tinea is second only to acne as the most frequently reported skin disease. More than 40 species are identified, but only 11 *Microsporum*, 16 *Trichophyton*, and 1 *Epidermophyton* species are known to cause human infections. Tinea capitis in the United States is caused overwhelmingly by *T tonsurans*, with

*Assistant Professor of Pediatrics, Wayne State University, Children's Hospital of Michigan, Detroit, Mich.

Table 1. Dermatophyte Infections

Name	Location	Condition	Comments
Tinea capitis	Scalp	Scaling, patchy alopecia; pruritus, pustules, black dots, suboccipital lymphadenopathy; kerion (see Table 2 for detailed presentations)	Most common in prepubertal children. Caused by <i>Trichophyton</i> or <i>Microsporum</i> sp. Most common in United States is <i>T tonsurans</i> , <i>M canis</i> (from dogs and cats), <i>M gypseum</i> (most common geophilic species).
Tinea corporis	Glabrous skin (smooth and bare)	Typical annular lesion, red and scaly with active erythematous border, often with central clearing; multiple lesions may overlap	All species of <i>Trichophyton</i> , <i>Microsporum</i> , and <i>Epidermophyton</i> cause infection. Most common in United States is <i>T rubrum</i> , <i>T tonsurans</i> , <i>T mentagrophytes</i> , <i>M canis</i> , and <i>E floccosum</i> . <i>T violaceum</i> common in India and Africa. Animals may host specific dermatophytes.*
Tinea faciale Tinea faciei	Face	Annular, scaly plaque as above; may lack red, scaly border	3% to 4% of tinea corporis. Common in children. Steroids cause altered lesions referred to as <i>T incognito</i> .
Tinea cruris	Groin areas	Intense pruritus; multiple erythematous papulovesicles that have well-margined, raised borders; spares scrotum	Primarily in adolescent and adult males. Commonly <i>T rubrum</i> , <i>E flocculosum</i> , <i>T mentagrophytes</i> . Organism depends on prevalence in population. Secondary changes complicate presentation (lichenification, infection, allergy).
Tinea manuum Tinea pedis ("athlete's foot")	Hands (palms) Feet	Presentations <u>Interdigital or intertriginous:</u> erythematous, scaly, foul odor, maceration of toe web spaces <u>Moccasin:</u> erythema, fissuring, dry, scaly, hyperkeratotic on plantar surfaces and lateral margins <u>Vesicular:</u> inflammation with vesicles or larger bullae	Hands and feet have similar presentations. Less likely before puberty. <i>T rubrum</i> , <i>T mentagrophytes</i> , <i>E floccosum</i> most common. Interdigital is the most common type.
Tinea unguium Onychomycosis [†]	Nails	Causes fungal nail dystrophy in several forms: distal, proximal, superficial, total dystrophic; nail plate may be friable and thick, destroyed, or show white spots	Uncommon in children; parents usually are infected when this is found in child. Most often <i>T rubrum</i> , <i>T mentagrophytes</i> , <i>E floccosum</i> .
Tinea barbae	Beard	Pustules; purulent papules; exudates; crusting, boggy nodules; hair loss	Usually in adolescent and adult males. Most are from zoophilic species in rural areas: <i>T mentagrophytes</i> , <i>T verrucosum</i> , <i>T violaceum</i> , and <i>T rubrum</i> .

*Examples of zoophilic dermatophytes and their animal hosts: *M canis* in dogs and cats, *T verrucosum* in cattle, *M equinum* and *M praecox* in horses, *M nanum* in pigs, *T erin* in hedgehog in United Kingdom and New Zealand, *T simii* in monkeys in India, *T mentagrophytes* in many animals.

[†]Onychomycosis refers to nail infection caused by fungus. Tinea unguium describes dermatophytic infection of the nail plate.

Adapted from Nelson M, Martin A, Heffernan M. Superficial fungal infection: dermatophytosis, onychomycosis, tinea nigra, piedra. In: Freedberg IM, Eisen AZ, Wolff K, Austen KF, Goldsmith LA, Katz A, eds. *Fitzpatrick's Dermatology in General Medicine*. 6th ed. New York, NY: McGraw-Hill Professional; 2003:1989–2005.

the occurrence among urban black children reaching epidemic proportions. Tinea corporis due to this organism occurs frequently in the same geographic areas. Before 1960, *M audouinii* was the predominant cause of scalp infection in the United States, Europe, and parts of Africa, but it comprised only 0.3% of cases in the United States in a 1979 to 1981 survey.

Tinea capitis is most common in children younger than 10 years of age, with a peak occurrence at 3 to 7 years. However, *T tonsurans* can be cultured from asymptomatic adults in families having active disease and from asymptomatic classmates. The age predilection is believed to result from the fungistatic properties of short- and medium-chain fatty acids in postpubertal sebum and

possibly the presence of *Pityrosporum ovale*, part of the normal adult flora.

Pathogenesis

Dermatophytes produce enzymes such as keratinase that penetrate keratinized tissue. Their hyphae invade the stratum corneum and keratin and spread centrifugally outward. Fungus invades the newly keratinized hair shaft as soon as it is formed at a rate of about 0.3 mm daily. Surface factors such as trauma, pH, carbon dioxide tension, and epidermal turnover may play a role in dermatophytic invasion. Host defenses against invasion include increased rate of epidermal turnover, serum inhibitory factors, fatty acids in sebum, and immune mechanisms, particularly T lymphocytes. Transferrins diffusing from the serum into the epidermis may delay fungal development by decreasing iron available for growth of the fungus.

The degree of epidermal inflammation results from an immunologically mediated reaction to fungal antigens in the stratum corneum. Inflammation varies among individuals and tends to be more prominent with the zoophilic species. Scaling results from increased epidermal replacement following inflammation.

Source of Infection

Transmission is by infective spores (arthroconidia), which are spread by fallen hair, desquamated epithelium, and direct contact. Viable spores can be cultured from contaminated combs, hairbrushes, barbershop instruments, shared hats, clothing, bedding, and furniture. Asymptomatic carriers are common and may help perpetuate the infections. Zoophilic infection depends on the animal source and tends to lose virulence after about four human-to-human transmissions. The infected animal may be asymptomatic.

Diagnosis

The diagnosis can be made from history, clinical presentation, culture, and direct microscopic observation of hyphae in infected tissue and hairs after potassium hydroxide preparation. Culture is useful in tinea capitis and tinea unguium and in treatment failures at other sites. Organisms can be collected by scraping or brushing with a toothbrush or damp cotton swab at the leading edge of the infection and placing the material on a dermatophyte medium. Most dermatophytic media contain Sabouraud dextrose agar; chloramphenicol is added to inhibit bacterial growth and cycloheximide to inhibit saprophytic fungi. Adding phenol red changes the agar color in the presence of alkaline dermatophyte metabolites and iden-

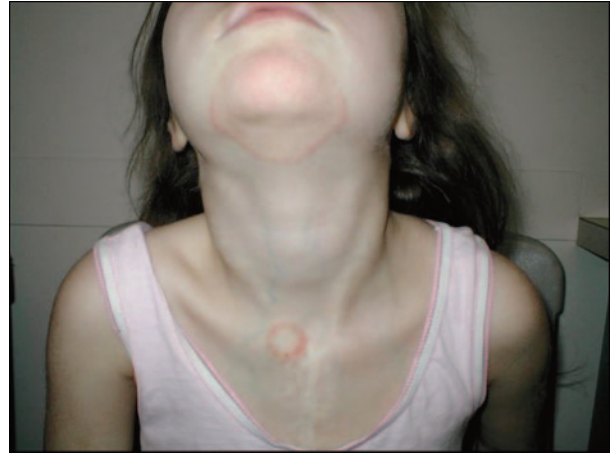

Figure 1. Tinea corporis on body and tinea facie. Note the erythematous border and scaling.

tifies growth. Wood lamp examination is not useful for most tinea capitis lesions because the majority of such infections are caused by endothrix species, and only ectothrix species fluoresce green-yellow under Wood lamp. Thus, *Trichophyton*, the most common species in the United States, does not fluoresce. Actual identification of dermatophyte species requires observation of morphology and microscopic examination in a suitable laboratory.

Tinea Corporis

Clinical Presentations

Tinea corporis often appears initially as a red, scaly papule spreading outward, with a coalescence of papules into plaques that become scaly (Fig. 1). The lesion becomes an annular, pruritic plaque on glabrous (smooth and

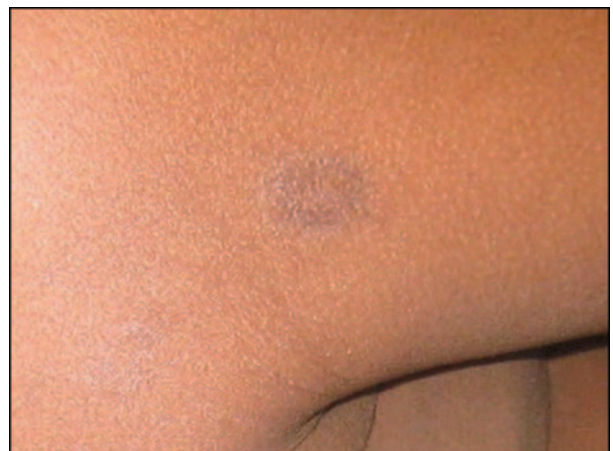

Figure 2. Tinea corporis, with raised papular border, some scaling, and central clearing.

bare) skin, with a scaly, slightly raised edge at the advancing border. The center may clear (Fig. 2), leaving a hypo- or hyperpigmented postinflammatory area as the lesion advances.

Tinea cruris causes a sharply demarcated, pruritic lesion that has a raised erythematous margin and thin, dry epidermal scaling that tends to spare the penis, scrotum, vulva, and perianal area, in contrast to candidiasis, which affects these areas. The rash spreads from the groin down the inner thigh. Tinea pedis or tinea unguium often are concomitant with tinea cruris.

Tinea pedis presents most often as a web-space maceration, but also may have a moccasin distribution, affecting the soles and lateral feet with hyperkeratotic scale. Tinea manuum manifests similarly and often accompanies tinea pedis. Scaling may be finer, with white or silvery scaling in the creases, or the typical tinea corporis pattern may be present. Tinea unguium affects the nail plate and is the most resistant to treatment, requiring long courses and having frequent relapses. The nail can show dystrophy, thickening, ridging, discoloration, and breakage or occasionally a superficial white discoloration on the nail surface. The more general term onychomycosis refers to any fungal infection of the nail, including yeasts that do not respond to griseofulvin.

Atypical presentations of tinea include tinea incognito, in which the characteristic scaling disappears after treatment of the lesion with high-potency steroid; bullous tinea corporis, in which herpetiform, subcorneal vesicles appear; tinea profunda, which is characterized by subcutaneous abscesses due to *T mentagrophytes*; verrucous lesions; and Majocchi granuloma, typified by nodular or kerionlike lesions not on the scalp. Tinea imbricate, caused by *T concentricum*, has multiple concentric rings and is found only in the western Pacific.

Differential Diagnosis

Other nondermatophytic fungi cause superficial infections. *Candida* infection has a more erythematous presentation and has an irregular shape and satellite lesions at the edge of an inflamed area. Tinea versicolor now is referred to commonly as *Pityrosporum versicolor* to differentiate it from dermatophyte infections because it is not a true tinea. It is caused by a filamentous form of *Malassezia furfur* (*P orbiculare* is the yeast form). Multiple oval, hypo- or hyperpigmented, macular lesions that have very fine scales usually appear on the upper trunk, face, and proximal arms. The condition usually is asymptomatic, chronic, and more prominent when sun-exposed areas fail to tan. The rash can be pruritic, espe-

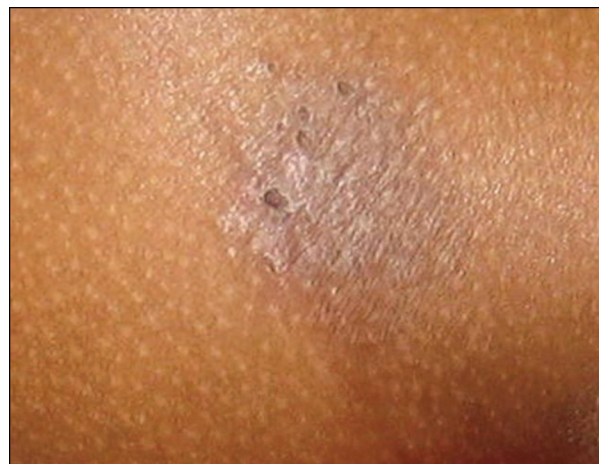

Figure 3. Nummular eczema, showing typical crusting without central clearing.

cially with sweating or warm weather, and fluoresces blue-white, yellow, or coppery under a Wood lamp.

Nummular eczema appears as a coin-shaped scaly patch without central clearing (Fig. 3). The lesions tend to be more numerous and have no advancing border. Pruritus varies.

Granuloma annulare lesions are nonpruritic, flesh-colored dermal papules in a ringlike distribution that have no scaling or erythema over the nodules (Fig. 4). The papules or nodules in annular rings have clear centers that vary from 1 to 5 cm in diameter and usually appear on the hands or arms. The lack of scale is an important differentiating feature. The lesions usually disappear spontaneously over months to years.

Impetigo, caused by bacterial infection, can form circular, crusted lesions that occasionally are confused

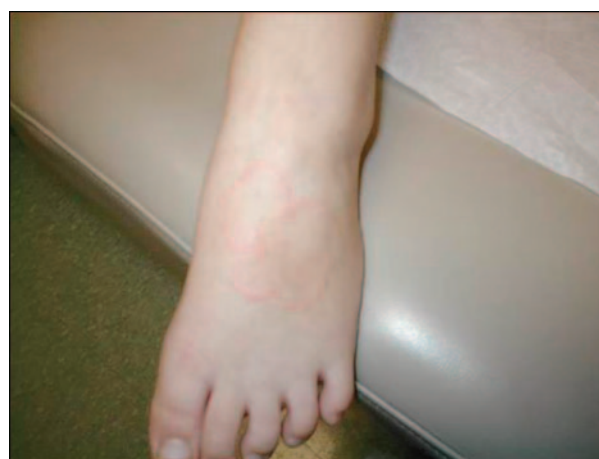

Figure 4. Granuloma annulare. Note the lack of scaling.

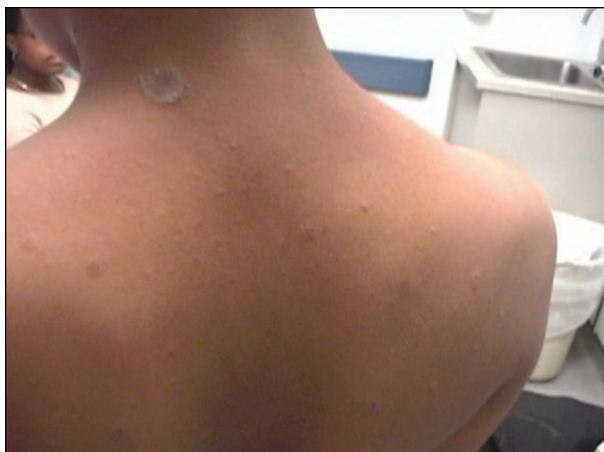

Figure 5. Herald patch of pityriasis rosea on neck.

with excoriated tinea lesions or may coexist with dermatophytes.

Discoid lupus, a well-circumscribed, elevated, indurated red-to-purplish plaque that has adherent scale and fine telangiectasia, is seen particularly on the face and resembles tinea faciale.

Pityriasis rosea starts as a herald patch (Fig. 5), which is a sharply defined oval patch of skin-colored, scaly dermatitis that has a red, finely scaled, slightly elevated border and evolves into a more diffuse eruption of skin-colored papules in a dermatomal or Christmas tree-like pattern. The herald patch can resemble early tinea, and the later diffuse lesions resemble the id reaction associated with tinea capitis.

Annular lichen planus consists of shiny, flat-topped, polygonal lesions in a ringlike grouping, commonly occurring on the penis and lower trunk, and resembles granuloma annulare.

Psoriatic plaque can present with erythematous lesions that have a diffuse, thick white scale.

Lesions of tinea pedis may resemble peridigital atopic dermatitis, which is more common in children than is tinea.

Contact dermatitis from shoe contact is found more commonly on the dorsum, whereas tinea usually has a moccasin distribution. *Candida* infection may have a similar clinical appearance.

Tinea Capitis

Tinea capitis has a broad range of clinical presentations that may be inflammatory or noninflammatory, manifesting with or without erythema (Table 2) (Figs. 6–12). Posterior cervical and suboccipital lymphadenopathy often accompany scalp infection. Tinea capitis should be

Table 2. Clinical Presentation of Tinea Capitis

- **Diffuse scaling:** Seborrhealike or dandruff pattern throughout the scalp. The flaking sometimes is masked by hair oils, so chronic pruritus may be the presenting complaint.
- **Moth-eaten:** Hair loss is patchy; scalp may be scaly.
- **Gray type:** Circular patches of alopecia with marked scaling. Spores on the outside of the hair shaft cause gray-tinged hair. Hair breaks several millimeters above the scalp and is typical of *M audouinii*.
- **Diffuse pustular:** Widespread pustules on the scalp. Sometimes mistaken for pustulosis, particularly in tightly braided hair.
- **Black dot:** Pattern presents with well-demarcated area of hair loss with hairs broken off at follicular orifice, which gives the appearance of black dots on the scalp in the area of alopecia. May also be inflammatory and is most common in endothrix species because spores within hair shaft cause breakage at level of the scalp.
- **Kerion:** An inflammatory lesion that has an edematous, boggy swelling with or without pustules. Inflammation may leave scarring. Purulent material may ooze from follicular orifices. Pruritus, regional lymphadenopathy, and sometimes pain and fever may occur.
- **Favus:** Severe, chronic form causing a thick yellow coating on hair; uncommon in the West; caused by *Trichophyton schoenleinii*.

Adapted from Paller AS, Mancini AJ. Skin disorders due to fungi. *Hurwitz Clinical Pediatric Dermatology*. 3rd ed. Philadelphia, Pa: Elsevier; 2006:449–478.

included in the differential diagnosis of any scaling scalp lesion, especially if it is associated with hair loss. Several other conditions can be mistaken for tinea capitis (Table 3), including kerion (Figs. 13, 14). In children beyond early infancy and not yet teenagers, flaking of the scalp should be cultured because seborrheic dermatitis is unlikely at this age. Allergic contact dermatitis and psoriasis also may cause flaking. Pustular folliculitis should be cultured if any hair loss is present because tinea also can be follicular.

An id (dermatophytid or identity) reaction is a fungus-free papular eruption, often follicular, resembling pityriasis or tinea lesions on the trunk, ears, and face. The id reaction frequently is a cell-mediated immune response to dermatophytes and sometimes occurs after the start of treatment. This condition usually resolves spontaneously.

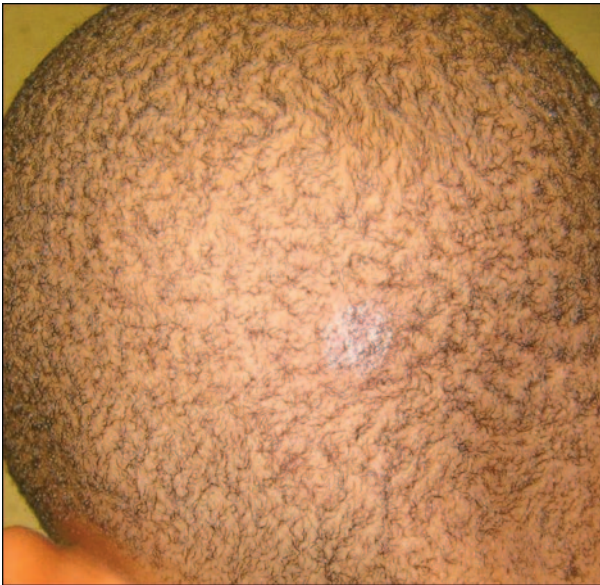

Figure 6. Tinea capitis characterized by gray, patchy scaling with alopecia. Lesion was noted after a haircut.

Management of Tinea Infections

Tinea corporis usually is treated with topical antifungal preparations (Table 4). Tinea capitis always requires oral therapy.

Topical treatment usually is continued for 1 to 2 weeks after the lesion has resolved. Tineas are resistant to nystatin, an antifungal commonly used for *Candida* infections. Folk remedies, such as creating a chemical

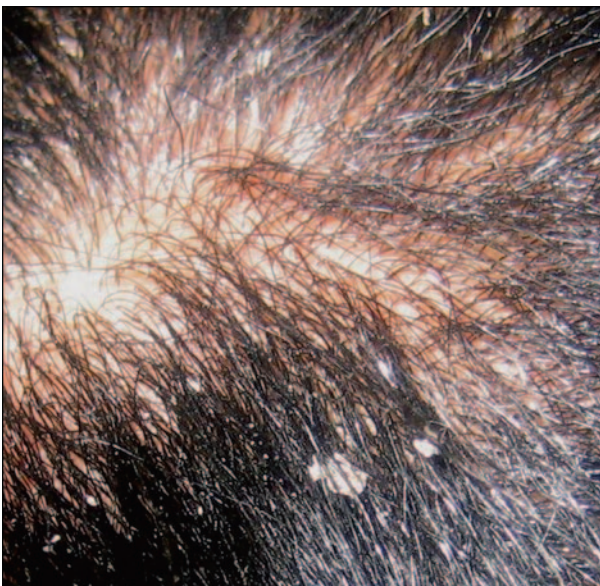


Figure 7. Tinea capitis, showing diffuse flaking and scale that resembles seborrhea.

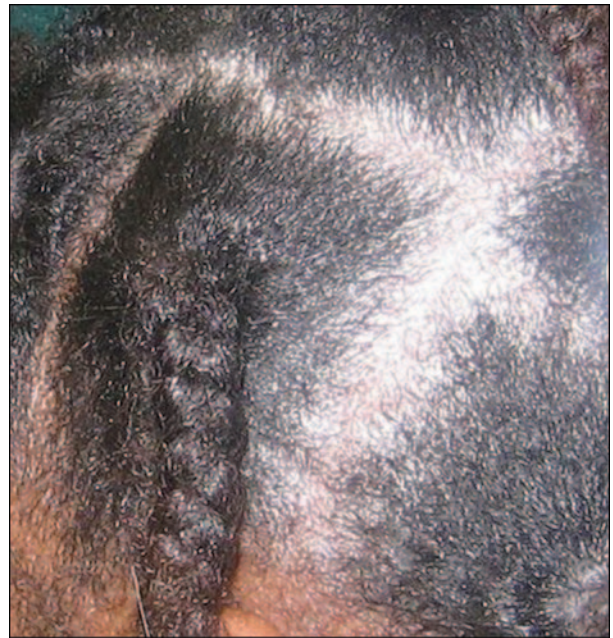

Figure 8. Tinea capitis characterized by thick white crusting of scalp. Note hair loss with widening of hair part and compare with normal hair part in front of the braid.

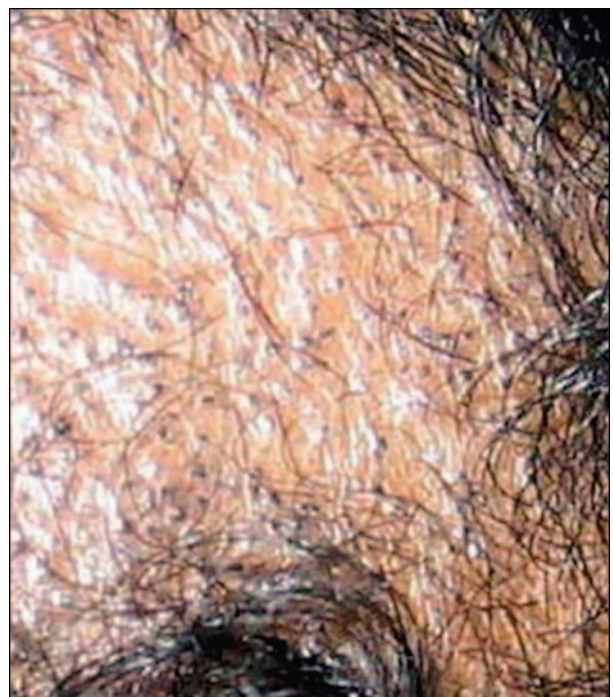

Figure 9. Tinea capitis, showing black dots from broken hairs in area of hair loss.



Figure 10. Tinea capitis in close up, showing white crusting around hair root and some broken hairs.

burn at the site with undiluted bleach, should be discouraged because they can cause infection and scarring. Topical therapy should be applied at least 2 cm beyond the edge of the lesions once or twice daily for 2 weeks, depending on the agent. If the lesion persists after 4 weeks of topical therapy, it is considered a treatment failure. Extensive, severe, or resistant cases of tinea corporis may require systemic treatment (Table 5).

Infection of hair or nails in tinea capitis, tinea barbae, and tinea unguium requires systemic treatment because topical antifungal medications do not penetrate into the

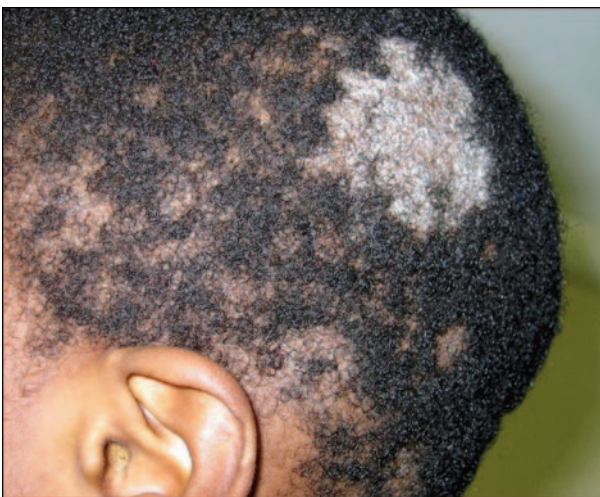

Figure 11. Tinea capitis that was resistant to high-dose griseofulvin after 6 weeks of treatment. Some of the smaller lesions are new. Culture grew *T tonsurans*.

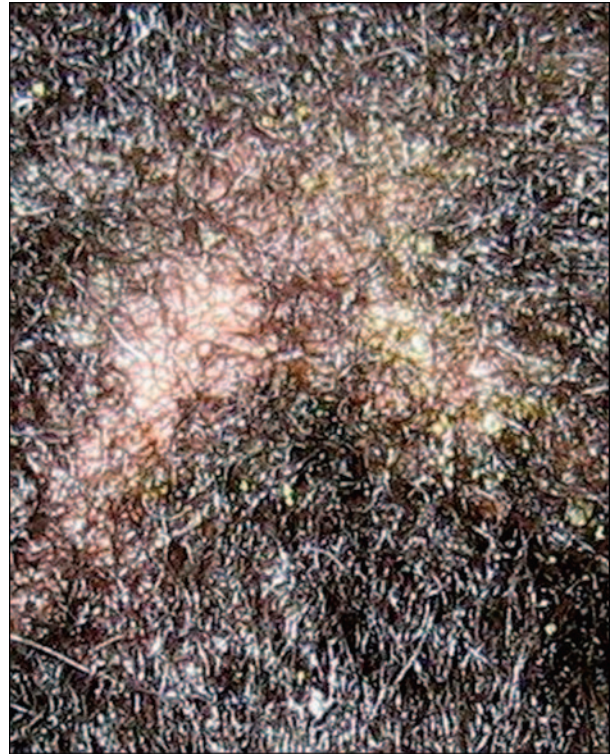

Figure 12. Tinea capitis, showing both white scales and yellow, purulent exudates with hair loss that was very pruritic. Child had been scratching her head constantly during a routine physical examination. Culture grew *T tonsurans*.

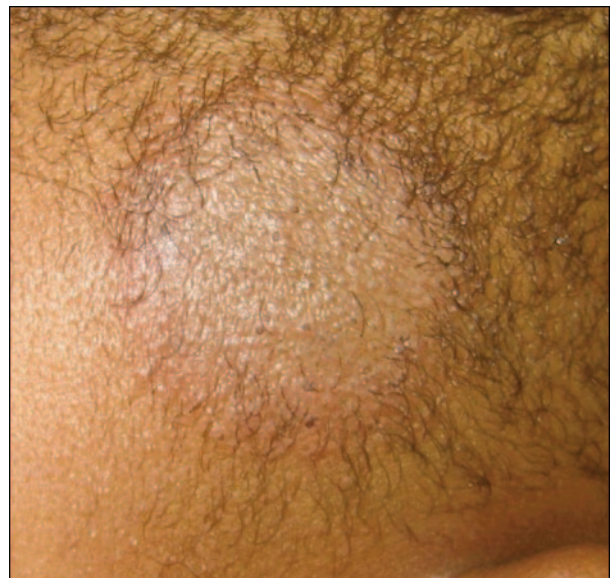

Figure 13. Kerion with boggy early lesion and multiple broken hairs. Few small pustules are forming.

Table 3. Differential Diagnoses of Tinea Capitis Presentations

Sign	Differential Diagnosis
Scaling	Seborrhea, eczema, or psoriasis due to diffuse flaking and scaling
Alopecia	Trichotillomania: hairs are broken at varying lengths. Alopecia areata: sharply defined round or oval patches of sudden hair loss; skin is devoid of hair and has typical "exclamation mark" hairs on microscopic examination. Secondary syphilis: areas of alopecia have a moth-eaten appearance; traction alopecia with hair loss due to traction or trauma.
Pustules Kerion	Pustular folliculitis, often seen with tight braiding. May be mistaken for a primary bacterial infection such as impetigo, furunculosis, or abscess because of the inflammation and pus. Confusion may result in inappropriate medical or surgical treatment. Impetigo and seborrhea generally do not cause hair loss.

Adapted from Nelson M, Martin A, Heffernan M. Superficial fungal infections: dermatophytosis, onychomycosis, tinea nigra, piedra. In: Freedberg IM, Eisen AZ, Wolff K, Austen KF, Goldsmith LA, Katz A, eds. *Fitzpatrick's Dermatology in General Medicine*. 6th ed. New York, NY: McGraw-Hill Professional; 2003:1989–2005.

hair shaft and nails sufficiently to clear the infection. Culture rarely is needed for tinea corporis unless the diagnosis is questionable or the infection is severe or widespread. Culture more commonly is necessary with tinea capitis and tinea unguium.

General practitioners and dermatologists may have slightly different approaches. Many dermatologists document all infections with cultures and repeat cultures monthly until they are negative because clinical improvement may be dramatic despite a persistently positive culture. In a general pediatric practice, cultures often are reserved for cases in which the diagnosis is unclear, the condition is unresponsive, the patient relapses, or there is

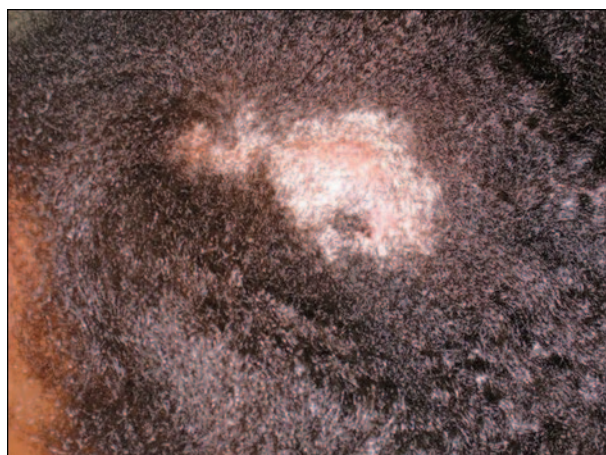

Figure 14. Kerion with boggy lesion, multiple pustules, and hair loss.

no dramatic improvement in the first month of treatment. All children should be seen and re-evaluated at least monthly. It is important to use the higher doses now recommended for griseofulvin (20 to 25 mg/kg for at least 2 mo). A full course of treatment should be administered to avoid recurrence or relapse.

Of the systemic therapies, griseofulvin remains the standard first-line treatment because it has a good safety profile and does not require blood tests. Griseofulvin inhibits nucleic acid synthesis, which arrests cell division at metaphase and impairs fungal cell wall synthesis. Because it is fungistatic and lipophilic, absorption is improved with the ingestion of fatty foods.

More recently, higher dosages or longer courses have been required, suggesting increasing resistance. Both tablet and suspension forms are available. Interactions occur with warfarin, cyclosporine, and oral contraceptives. Adverse effects are usually minor and consist primarily of gastrointestinal reactions or rashes.

Newer antifungal agents are the azoles itraconazole, fluconazole, and ketoconazole; the allylamine terbinafine; and the benzylamine butenafine. The azoles inhibit the enzyme lanosterol 14- α -demethylase, a cytochrome P450-dependent enzyme that converts lanosterol to ergosterol. This enzyme inhibition results in unstable fungal membranes and causes membrane leakage. The organism is unable to reproduce and is slowly killed by fungistatic action.

Fluconazole is more selective for cytochrome P450 enzymes than ketoconazole, reducing the potential for adverse drug interactions. It has excellent absorption and good persistence in tissue. Although fluconazole has not been approved for treating tinea in children, it is approved for candidiasis and cryptococcal meningitis in children, and in studies of treatment of tinea capitis, it generally has been found to be safe and effective both in continuous use for 3 to 6 weeks and in once-weekly dosing for 8 weeks.

Itraconazole has been used for systemic and superficial fungal infections of adults and children. Although not approved by the United States Food and Drug Administration (FDA) for children, it is considered to be safe and effective. Itraconazole should be taken after a meal. It has high affinity for keratin, accumulating to

Table 4. Common Topical Antifungal Therapies and Relative Cost

Drug Class	Drug Name	Dose (2 to 4 weeks)	Cost [†] US\$
Tolfanate	Tolfanate	BID	\$
Imidazoles	Clotrimazole	BID	\$\$
	Miconazole	BID	\$\$
	Econazole	QD	\$\$
	Ketoconazole	QD	\$\$
	Oxiconazole	QD to BID	\$\$\$
	Sulconazole	QD	\$\$
Ciclopirox*	Ciclopirox	BID	\$\$\$
Benzylamine	Butenafine	QD to BID	\$\$\$
Allylamine	Terbinafine	BID	\$\$
	Naftifine	QD, BID	\$\$\$\$

*Safety and efficacy not established for children <12 years of age.
[†]Cost based on the average wholesale price in 2003.
 \$ = \$1 to \$8; \$\$ = \$8 to \$20; \$\$\$ = \$21 to \$40; \$\$\$\$ = \$40 to \$50.

levels 2 to 20 times that in serum, and persists for 4 weeks in skin and 9 to 12 months in toenails. It interacts with drugs that use P450 enzymes. Pulse dosing of daily therapy for 1 week, followed by 3 weeks off and repeating the cycles, has been successful. Lower gut pH may reduce absorption, particularly in neonates. Capsules can be opened and sprinkled on food. A liquid form is available, but the vehicle has caused pancreatic carcinoma in rats.

The allylamines and the related benzylamine, butenafine, inhibit squalene, an epoxidase that converts squalene to ergosterol, causing intracellular accumulation of a toxic substance that leads to rapid

Table 5. Medication Used in the Treatment of Tinea Capitis

Drug Name	Pediatric Dosage	Course (wk)	Suspension Capsule/ Tablets	Cost [†]	Cost [†] (1 mo 20 kg)	Benefits/Risks
Griseofulvin microsized	20 to 25 mg/kg per day QD or BID	6 to 8	25 mg/mL	\$0.35/mL	\$168	<ul style="list-style-type: none"> • Treatment of choice • Long clinical experience of safety • No laboratory tests needed
			125 mg tabs	\$1.05/tab	\$94	
			250 mg tabs			
			500 mg tabs			
Itraconazole*	3 to 5 mg/kg per day QD	4 to 6	10 mg/mL	\$0.93/mL	\$280	<ul style="list-style-type: none"> • Liquid: cyclodextrin vehicle causes cancer in rats • Many cytochrome P450 drug interactions • Monitor liver function tests[§]
			100 mg caps	\$9.64/caps	\$289	
	>49 kg: 100 mg/d Also has been used as pulse therapy*	2				<ul style="list-style-type: none"> • Many cytochrome P450 drug interactions • Monitor liver function tests[§]
Fluconazole*	5 mg/kg per day QD	4 to 6	10 mg/mL	\$1.14/mL	\$342	<ul style="list-style-type: none"> • Shorter therapy • Many cytochrome P450 drug interactions • Monitor liver function tests[§]
			40 mg/mL	\$4.15/mL	\$311	
	6 mo	20 d	50 mg tabs	\$6.22/tab	\$373	
			100 mg tabs	\$9.28/tab	\$278	
	6 mg/kg per day		200 mg tabs	\$16.01/tab	\$240	
Terbinafine*	<20 kg: 62.5 mg/d 20 to 40 kg: 125 mg/d >40 kg: 250 mg/d QD Also has been tried in weekly pulse therapy	2 to 4	250 mg tabs	\$10.62/tab	\$159	<ul style="list-style-type: none"> • Shortest therapy • Pulse therapy possible • Many drug interactions • Monitor liver function tests[§] • Bactericidal

*Not approved therapy by United States Food and Drug Administration; patient must have failed high-dose griseofulvin therapy.
[†]Average wholesale price in 2004; retail cost is higher.
[§]Manufacturer recommends liver function tests at baseline and again if therapy is continued for >4 wk.

fungal cell death. Ciclopirox accumulates inside cells, interfering with amino acid transport and causing fungal cell membrane instability.

Terbinafine, a well-absorbed fungicide, accumulates in skin at higher concentrations than in plasma and has a long half-life. In comparative studies, terbinafine treatment for 4 weeks gave similar cure rates of *Trichophyton tinea capitis* as 8 weeks of griseofulvin.

Onychomycosis in children in North America has no FDA-approved treatment. However, terbinafine is the recommended drug for treating nail dermatophytes; dosage is based on the child's weight, and the agent is taken for 6 to 12 weeks. Clearance is about 40% higher in children than in adults. Terbinafine is available only in tablets, but they can be broken, pulverized, and added to food.

Adjunctive therapy with antifungal shampoo 2 to 3 times weekly for the patient who has tinea capitis as well as for family members is recommended to reduce the number of spores. The most commonly recommended is selenium sulfide 2.5% shampoo, which adheres to the scalp after rinsing. Ketoconazole shampoo seems less drying because of its coconut oil base but does not work as well because it rinses away more easily. This shampoo is more effective if left on for 5 minutes. Hair grooming practices do not appear to play a major role in acquiring tinea capitis. Hygienic practices such as not sharing combs, brushes, or hats are important to decrease transmission.

Exclusion from school is not recommended because spores can shed for months. Additionally, asymptomatic carriers within the class who can be vectors are common.

Summary

Tinea capitis and corporis are very common in children. Tinea capitis usually is caused by nonfluorescent *T ton-*

surans in the United States. It has many presentations, from mild flaking to purulent infected areas, but usually causes pruritus, hair loss, and often, suboccipital adenopathy. Oral antifungal treatment always is required for tinea capitis, although shampoos may decrease the risk of transmission. Children should not be excluded from school because they remain infective and there likely are asymptomatic carriers in the class. Tinea corporis may vary in presentation on different parts of the body. Some children manifest an id reaction, which is an allergic response to the fungal antigens rather than to the medication.

Suggested Reading

- Clayton YM. Superficial fungal infections. In: Harper J, Oranje A, Prose N, eds. *Textbook of Pediatric Dermatology*. Oxford, United Kingdom: Blackwell; 2000:447–459
- Gupta AK, Cooper EA, Ginter G. Fluconazole, terbinafine and itraconazole in the treatment of superficial fungal. *Dermatol Clin*. 2003;21:511–542
- Higgins EM, Fuller LC, Smith CH. Guidelines for the management of tinea capitis. British Association of Dermatologists. *Br J Dermatol*. 2000;143:53–58
- Kao GF. Tinea capitis. *eMedicine Dermatology Fungal Infections*. 2006. Available at: <http://www.emedicine.com/derm/topic420.htm>
- Leyden JJ. Update on tinea capitis and new antifungal therapies. *Pediatr Infect Dis J*. 1999;18:180–215
- Rushing ME, Johnson A, Zember G, Leshner JL. Tinea corporis. *eMedicine Dermatology Fungal Infections*. 2006. Available at: <http://www.emedicine.com/derm/topic421.htm>
- Stein DH. Fungal, protozoan and helminth infections. In: Schachner LA, Hansen RC, eds. *Pediatric Dermatology*. 2nd ed. New York, NY: Churchill Livingstone; 1998:1295–1311

PIR Quiz

Quiz also available online at www.pedsinreview.org.

1. The dermatophyte infections in humans can have a variety of clinical presentations and appearances that can provide the clinician with some diagnostic challenges. A black dot skin appearance is *most* likely seen in:
 - A. Tinea capitis.
 - B. Tinea corporis.
 - C. Tinea cruris.
 - D. Tinea faciei.
 - E. Tinea pedis.
2. A 5-year-old boy enjoys playing with the cats that inhabit his neighborhood. He presents to your office with several raised, circular lesions on his arm and leg. You suspect that the child has tinea corporis acquired from his close contact with the cats. You scrape the lesions for a confirming fungal culture. The *most* likely zoophilic dermatophyte to cause the lesions is:
 - A. *Microsporum canis*.
 - B. *M nanum*.
 - C. *M praecox*.
 - D. *Trichophyton erin*.
 - E. *T simii*.
3. A previously useful diagnostic test for helping to diagnose suspected cases of tinea capitis was the detection of green-yellow fluorescence in the hair roots with a Wood lamp. The *primary* reason this test is less helpful today is the declining incidence of:
 - A. Ectothrix infections.
 - B. Endothrix infections.
 - C. Geophilic infections.
 - D. *M canis* infections.
 - E. *Trychophyton* infections.
4. A number of skin conditions must be considered in the differential diagnosis of tinea corporis. One disorder that resembles tinea corporis but is notable for its *lack* of scale is:
 - A. Discoid lupus.
 - B. Granuloma annulare.
 - C. Nummular eczema.
 - D. Pityriasis rosea.
 - E. Psoriasis.